
Considerations for addition of “Remplissage” procedure for engaging Hill-Sachs lesions in combination with arthroscopic Bankart repair.

Description of the problem: When an anterior dislocation is sustained, it is frequently accompanied by a Hill-Sachs lesion—an osteochondral “divot” on the posterior aspect of the humeral head. When this lesion is sufficiently large, it may engage the anterior glenoid during abduction and external rotation of the arm. This engaging Hill-Sachs lesion is associated with recurrent shoulder instability, even after the anterior Bankart lesion is fixed. Several surgical solutions have been proposed for the engaging Hill-Sachs lesion, and one is the “remplissage,” from the French word meaning “to fill in.”

Description of the surgery: Remplissage added to anterior Bankart repair involves filling in the Hill-Sachs defect with posterior capsular tissue and the infraspinatus tendon (capsulotenodesis). Suture anchors are used to tack this tissue into the superior and inferior aspect of the medial border of the Hill-Sachs lesion. This procedure results in the Hill-Sachs lesion being extra-articular and acts as a “check-rein” to resist anterior translation of the humeral head on the glenoid, and has been shown in randomized trials to decrease the incidence of recurrent instability and improve outcome scores.

Implications for rehabilitation: Given that the remplissage involves a tenodesis of the Infraspinatus (ISp) into the Hill-Sachs defect, the healing timeframes associated with rotator cuff repair must be considered in order to optimize the healing of the tendon into the defect. As such, active and passive tension across this repair should be avoided for the first 6 weeks following surgery, and resistance to the posterior cuff avoided for 12 weeks. Based on these timeframes the following modifications to the anterior shoulder reconstruction rehab model follow remplissage:

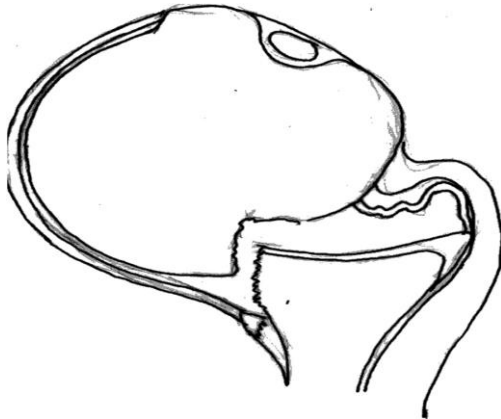
Phase 1 (0-6 weeks): All ER ROM should be passive using the well arm within the precautionary range limits (after anterior Bankart without remplissage, the range can be active with precautionary limits when tolerated by the patient since there is not concomitant rotator cuff repair).

Phase 2 (6-12 weeks): Do not initiate cross body or sleeper stretch (which are initiated in this phase for anterior capsulolabral reconstruction) as this may be too much passive tension on the posterior capsule and ISp; do not initiate theraband or isometrics for ER as this may be too much active tension on the ISp tenodesis. ER may be performed actively in available range in this phase without resistance. OK to strengthen IR, but avoid a lot of resistance for scapular retraction as this engages the posterior cuff.

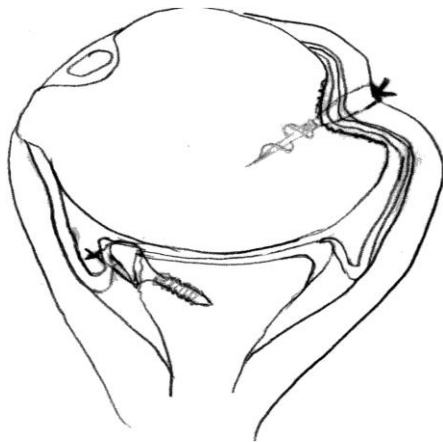Phase 3 (12 weeks onward): Begin very gentle and slow progression for cross body adduction and sleeper stretch; may initiate ER and scapular retraction resistive training at neutral and then work up to positions of elevation with theraband and/or progressive light weights.

Phase 4 (20+ weeks): Work and sport specific activities as usual

Engaging Hill-Sachs lesion and Bankart lesion



Remplissage and Bankart repair



References:

Buza JA, Iyenagar JJ, Anakwenze OA, Ahmad CS, and Levine WN: Arthroscopic Hill-Sachs remplissage: a systematic review. *J Bone Joint Surg Am.* 2014 Apr 2;96(7):549-55.

Elkinson I, Boons H, Faber K, Ferreira L, Johnson J, Athwal G: The shoulder remplissage procedure for Hill-Sachs defects: does technique matter? *JSES* 22(6) 2013, 835–841.

Wolf E, Arianjam A: Hill-Sachs remplissage, an arthroscopic solution for the engaging Hill-Sachs lesion: 2- to 10-year follow-up and incidence of recurrence. *JSES* 23(6) 2014, 814–820.